OCR
Oxford Cambridge and RSA

Monday 17 June 2019 – Morning

A Level Biology B (Advancing Biology)

H422/03 Practical skills in biology

Time allowed: 1 hour 30 minutes

You must have:
- the Insert (inserted)
- a ruler (cm/mm)

You may use:
- a scientific or graphical calculator

Please write clearly in black ink. **Do not write in the barcodes.**

Centre number | | | | | | Candidate number | | | | |

First name(s) _____

Last name _____

INSTRUCTIONS
- The Insert will be found inside this document.
- Use black ink. You may use an HB pencil for graphs and diagrams.
- Answer **all** the questions.
- Where appropriate, your answers should be supported with working. Marks may be given for a correct method even if the answer is incorrect.
- Write your answer to each question in the space provided. If additional space is required, use the lined page(s) at the end of this booklet. The question number(s) must be clearly shown.

INFORMATION
- The total mark for this paper is **60**.
- The marks for each question are shown in brackets **[ ]**.
- Quality of extended responses will be assessed in questions marked with an asterisk (*****).
- This document consists of **16** pages.

© OCR 2019 [601/4720/9]
DC (RW/TP) 174987/4
OCR is an exempt Charity

Answer **all** the questions.

1 A student was learning about the heart and circulatory system. The student dissected a heart and made a drawing of their dissection as shown in Fig. 1.1.

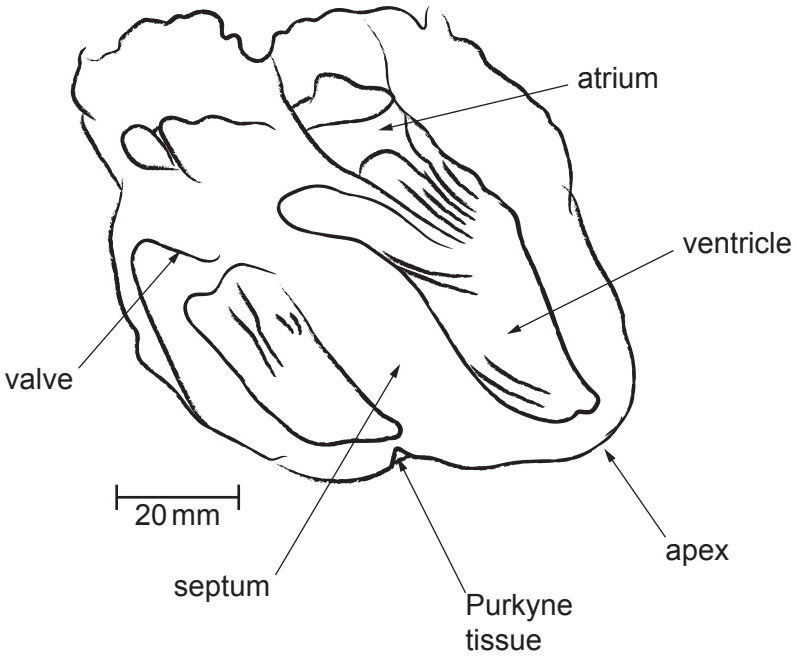

Fig. 1.1

(a) Suggest **two** improvements that could be made to the drawing in Fig. 1.1.

1 .....

.....

2 .....

.....

[2]

© OCR 2019

(b) The student was given a microscope slide of a large artery. The image seen is shown in Fig. 1.2, **on the insert**.

A small part of the image in Fig. 1.2 has been enclosed in a rectangle.

Using the space below, draw an annotated low power plan of the part of the artery shown within the rectangle in Fig. 1.2.

[4]

© OCR 2019

2 Fallopian tube cancer may result in the formation of tumours in the epithelial tissue lining the Fallopian tubes.

(a) Name the type of cell division that occurs in a tumour.

..... **[1]**

(b) The table below contains information about some of the methods used for detecting cancer.

Complete the table by inserting the missing information.

Method used to detect cancer	What does the method involve?	Which parts of the body are examined?
Blood test	antibody test (ELISA)	blood
Mammography	low energy x-rays	.....
CT scan	.....	whole body scans
.....	high frequency sound waves	soft tissue
MRI scan	..... field and ..... waves	soft tissue, bone, brain or spinal cord tumours
.....	radioactive tracer and gamma waves	produces three-dimensional images of any part of the body
Biopsies	needle, scalpel or speculum	tissues identified as possible tumours

[5]

© OCR 2019

(c) Fallopian tube cancer treatment often results in infertility. Patients whose treatment has resulted in infertility may be offered egg freezing and subsequent *in vitro* fertilisation (IVF) treatment at a fertility clinic.

Fertility clinics have different mean annual pregnancy rates. Table 2.1 contains some information about mean annual pregnancy rates in two clinics each treating 400 patients.

	Mean annual pregnancy rate (% embryos transferred)
Clinic A	23
Clinic B	16

Table 2.1

The standard deviation, *s*, for both means is 9.7.

The Student's *t*-test can be performed to compare the mean annual pregnancy rate at each clinic and determine if the two are significantly different from each other.

(i) State the null hypothesis for this test.

.....

..... **[1]**

(ii) Calculate the variance, s^2, for these means.

variance = ... **[1]**

(iii) Calculate the *t* value for the data in Table 2.1.

Use the formula:

$$t = \frac{|\bar{x}_A - \bar{x}_B|}{\sqrt{\frac{s_A^2}{n_A} + \frac{s_B^2}{n_B}}}$$

Give your answer to **three** decimal places.

t = ... **[3]**

© OCR 2019

(iv) Critical values for degrees of freedom >100 are shown in Table 2.2.

Degrees of freedom	**Level of probability**		
	0.05	**0.01**	**0.001**
>100	1.960	2.576	3.291

Table 2.2

Using Table 2.2 and your answer to **(c)(iii)**, comment on the mean annual pregnancy rates for clinics A and B.

.....

.....

.....

.....

..... **[3]**

© OCR 2019

(d) The stages in one type of IVF treatment are shown below:

1. Hormones are used to stimulate several follicles within the ovary to mature at the same time.

2. Follicles are collected from the ovaries and the oocytes removed.

3. These oocytes are mixed with sperm in a Petri dish.

4. After several days the oocytes are checked for fertilisation.

5. Any resulting embryos are left to develop in an incubator for two to five days.

6. One embryo is transferred into the uterus.

During this treatment:

- The typical number of oocytes collected during stage 2 is between 5 and 25.
- Approximately 50% of the oocytes collected will be fertilised during stage 3.
- Of the total number of oocytes collected during stage 2, about 25% will result in a healthy embryo.

Discuss the ethical issues raised by this type of IVF.

You should use the information provided in your answer.

.....

.....

.....

.....

.....

.....

.....

.....

.....

..... **[4]**

© OCR 2019

3 A student was asked to find out the glucose concentration in mock body fluids. The student was provided with **three** samples. The student's plan contained the following apparatus list:

- test tubes
- 5 cm^3 syringes
- water bath set at 100 °C
- colorimeter fitted with a red filter
- cuvettes
- balance measuring in grams – 2 decimal place display
- filter papers and funnels
- table of data showing absorbance of 1, 5, 10 and 20 mmol dm^{-3} glucose solutions when tested with quantitative Benedict's reagent.

The student was given the choice of two methods, shown in Table 3.1.

Method 1 **Benedict's reagent**	**Method 2** **quantitative Benedict's reagent**
• Add 5 cm^3 of Benedict's reagent to a small volume of sample in a test tube. • Stand the test tube in boiling water for a few minutes. • Observe the colour change. A colour change from green to yellow, then to brown and finally to red indicates the presence of reducing sugar.	• Add 2 cm^3 of quantitative Benedict's reagent (QBR) to 4 cm^3 of sample in a test tube. • Stand the test tube in boiling water for 5 minutes. • Allow the tube to stand until the precipitate settles or filter to remove the precipitate. • Measure the absorbance using red light.

Table 3.1

The student chose to use method 2.

(a) Give **one** reason why the student chose method 2.

.....

..... **[1]**

© OCR 2019

(b)* Outline how the student could have used method 2 and the apparatus provided, to find out the glucose concentration in the samples of mock body fluids.

.....

.....

.....

.....

.....

.....

.....

.....

.....

.....

.....

.....

.....

.....

..... **[6]**

Additional answer space if required

.....

.....

.....

.....

.....

© OCR 2019

(c) A teacher was asked to comment on the method and results collected.

Complete the paragraph by choosing the most appropriate word from the list below.

anomaly **accuracy** **error** **limitation** **precision**

repeatability **reproducibility** **resolution**

The teacher suggested using a balance measuring in grams with a three decimal place display to improve ..... . After examining the results, the teacher concluded that the colorimeter had a zeroing error, limiting the ..... of the results. The teacher stated that one ..... of the investigation was that temperature was not controlled.

[3]

© OCR 2019

(d) The results of a similar investigation are shown in Table 3.2.

Location of body fluid sample	Mean concentration of glucose ($mmol\,dm^{-3}$)	Standard deviation
Bowman's capsule	15	2.0
Proximal convoluted tubule	4	0.7
Distal convoluted tubule	3	0.5

Table 3.2

(i) Use the grid provided to present these data in the most appropriate way.



[4]

(ii) A student concludes that these data came from a diabetic person.

Select **one** piece of evidence to support this conclusion.

.....

..... **[1]**

© OCR 2019

4 Programmed cell death is important in the growth and development of plants.

(a) **(i)** Name the process by which cells are destroyed in programmed cell death.

..... **[1]**

(ii) Suggest **one** tissue type in a mature plant which is **formed** by programmed cell death.

..... **[1]**

(b) Fig. 4, **on the insert**, is a photomicrograph of a root meristem and its root cap. A fluorescent staining technique has been used.

- The cells in the root cap are constantly dying and being replaced by new cells.
- The cells about to die have enlarged vacuoles.
- These enlarged vacuoles appear red in Fig. 4.

Suggest the benefit for the plant of having a root cap.

.....

..... **[1]**

(c) A researcher examined two photomicrographs similar to that shown in Fig. 4 for seedlings of different ages. The total number of cells present in the root cap and the number of cells with an enlarged red vacuole were counted. The results are shown in Table 4.

Age of seedling (days)	Number of cells with an enlarged red vacuole	Total number of cells in root cap
5	12	40
10	.....	85

Table 4

The researcher concluded that there was a 33% increase in the proportion of cells with an enlarged red vacuole between day 5 and day 10.

Calculate the number of cells with an enlarged red vacuole on day 10.

Give your answer to **2** significant figures.

[Write your answer in Table 4] **[2]**

© OCR 2019

(d) The root shown in the photomicrograph in Fig. 4 is from a plant classified in the group known as Eukaryota.

(i) To which taxonomic rank does Eukaryota belong?

..... **[1]**

(ii) The group Eukaryota includes both animal and plant species. There are similarities and differences in the ultrastructure of cells found in animal and plant species.

Use a tick (✓) or a cross (✗) to complete the table below to compare the features of these cells.

Feature	Present in animal cells	Present in plant cells
Mitochondria	✓	✓
Golgi apparatus		
Tonoplast		
Ribosomes		
Cell wall		

[4]

© OCR 2019

5 Fig. 5, **on the insert**, is a photomicrograph of a human ovary. Structures within the ovary have been labelled, **A** to **F**.

(a) Using Fig. 5, complete the table below by identifying the structure or label that best fits the description.

Description	**Structure**	**Label**
Supplies blood to the ovary	central coiled blood vessel	**F**
Contains receptors on plasma membranes for FSH		**A**
Releases oestrogen	follicle	
Contains a haploid nucleus		**E**
Produces progesterone		**D**
Gel layer composed of glycoproteins	zona pellucida	

[5]

© OCR 2019

(b)* The appearance of an ovary changes with age.

A student observed the ovary in Fig. 5 and concluded that this ovary was from a woman who had not yet started menopause.

Analyse Fig. 5 and comment on this conclusion.

.....

.....

.....

.....

.....

.....

.....

.....

.....

.....

.....

.....

.....

.....

..... **[6]**

Additional answer space if required

.....

.....

.....

.....

.....

END OF QUESTION PAPER

© OCR 2019

ADDITIONAL ANSWER SPACE

If additional space is required, you should use the following lined page(s). The question number(s) must be clearly shown in the margin(s).

OCR
Oxford Cambridge and RSA

Copyright Information

OCR is committed to seeking permission to reproduce all third-party content that it uses in its assessment materials. OCR has attempted to identify and contact all copyright holders whose work is used in this paper. To avoid the issue of disclosure of answer-related information to candidates, all copyright acknowledgements are reproduced in the OCR Copyright Acknowledgements Booklet. This is produced for each series of examinations and is freely available to download from our public website (www.ocr.org.uk) after the live examination series.

If OCR has unwittingly failed to correctly acknowledge or clear any third-party content in this assessment material, OCR will be happy to correct its mistake at the earliest possible opportunity.

For queries or further information please contact The OCR Copyright Team, The Triangle Building, Shaftesbury Road, Cambridge CB2 8EA.

OCR is part of the Cambridge Assessment Group; Cambridge Assessment is the brand name of University of Cambridge Local Examinations Syndicate (UCLES), which is itself a department of the University of Cambridge.

© OCR 2019